



[www.etsy.com/shop/Luotb](https://www.etsy.com/shop/Luotb)



@luotbstudies



@luotbstudies



Luotb Studies

**FOR PERSONAL USE ONLY. Please  
DO NOT share or resell my notes.**

# Axilla

The fossa between the lateral part of thorax upper part of humerus and lower part of the shoulder.

axilla is the passageway for the vessels and nerves from trunk to reach to the upper limb.

It is roughly pyramidal in shape, having an apex a floor and four walls.

## Walls of the axilla

- Lateral: intertubercular groove of the humerus
- Medial: 1st-4th ribs and associated intercostal muscles) and serratus anterior muscle

**Anterior** - Clavicle

**Posterior** - superior margin of the scapula

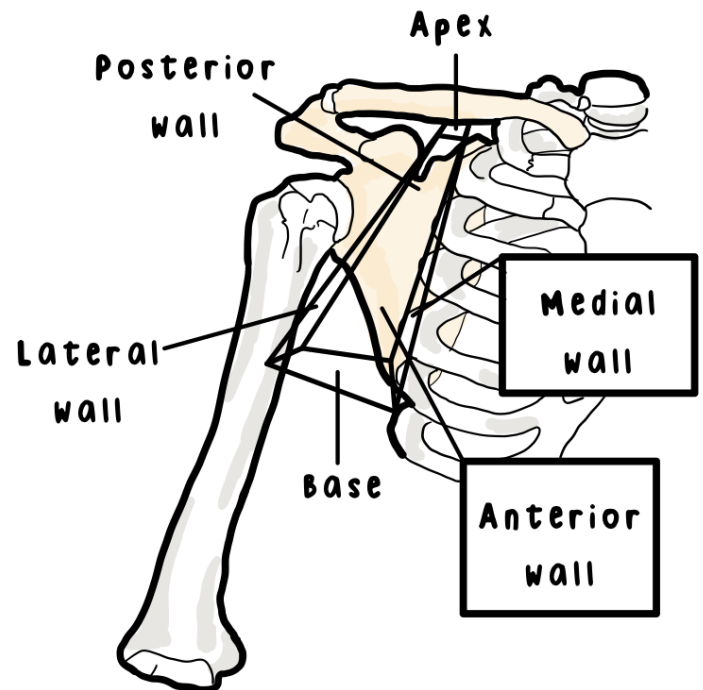
**Medial** - first rib

Axillary artery  
and its branches

Carry oxygenic  
blood **from**  
heart to the  
structures

Axillary vein and  
its branches

Carry  
deoxygenated  
blood **toward**  
heart



## Axillary artery

Axillary artery, axillary vein and the infraclavicular part of the brachial plexus is enclosed within a fascia called the axillary sheath.

## Axillary sheath

Axillary sheath is the continuation of the prevertebral layer of the deep cervical fascia.