

Axilla

The fossa between the lateral part of thorax upper part of humerus and lower part of the shoulder. axilla is the passageway for the vessels and nerves from trunk to reach to the upper limb. It is roughly pyramidal in shape, having an apex a floor and four walls.

Walls of the axilla

- Lateral: intertubercular groove of the humerus
- Medial: 1st-4th ribs (and associated intercostal muscles) and serratus anterior muscle

Anterior - Clavicle

Posterior - superior margin of the scapula

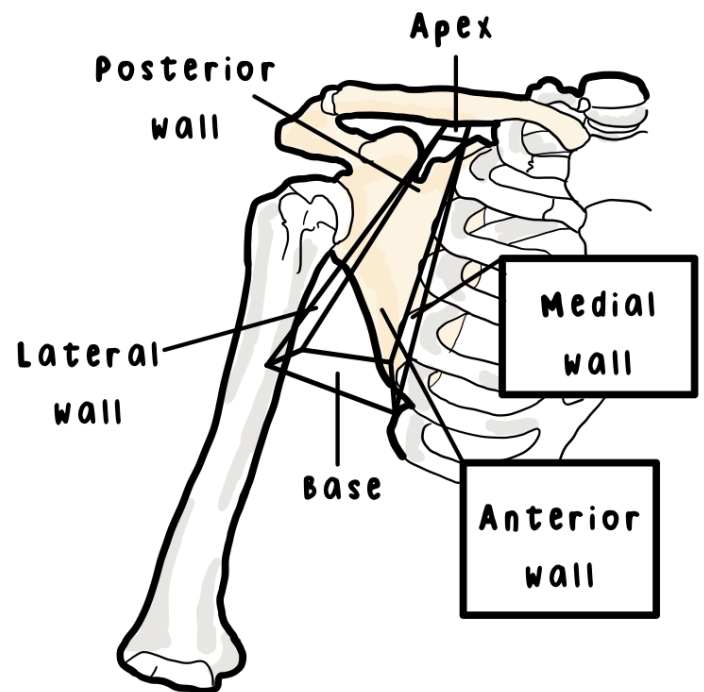
Medial - first rib

Axillary artery and its branches

Carry oxygenic blood **from** heart to the structures

Axillary vein and its branches

Carry deoxygenated blood **toward** heart



Axillary artery

Axillary artery, axillary vein and the infraclavicular part of the brachial plexus is enclosed within a fascia called the axillary sheath.

Axillary sheath

Axillary sheath is the continuation of the prevertebral layer of the deep cervical fascia.



www.etsy.com/shop/Luotb



@luotbstudies



@luotbstudies



Luotb Studies

**FOR PERSONAL USE ONLY. Please
DO NOT share or resell my notes.**