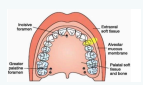 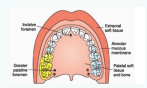 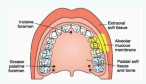 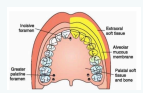 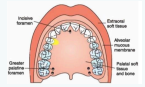 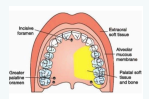 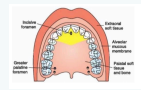 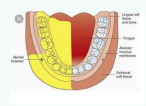 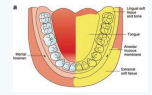 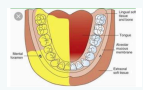 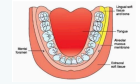

Techniques Of Anesthesia (Cheesy Table)

	Supraperiosteal injection (infiltration)	Posterior superior alveolar [nb] (PSA)	Middle superior alveolar nb (MSA)	Anterior superior alveolar nb (ASA)	Local Infiltration of the Palate
Other Names	Local infiltration, paraperiosteal injection	Tuberosity block, zygomatic block	No other name	Infraorbital nerve block	No other name
Nerves Anesthetized	dental plexus	Posterior superior alveolar nerve	middle superior alveolar nerve	1- Anterior superior alveolar nerve 2- Middle superior alveolar nerve 3- Infraorbital nerve a- Inferior palpebral (Lower eyelid) b- Lateral nasal (Part of the nose) c- Superior labial (Upper part of the lip)	Nasopalatine, Greater palatine
Area Anesthetized	pulp and root area ,PDL, buccal gingiva and mucosa periosteum and Bone. palatal site: mucosa and periosteumpal atal)	1- Pulps of the maxillary third, second, and first molars. 2- Buccal periodontiue and bone overlying	1. Pulps of the maxillary first and secondpre molars,mes iobuccal root of the first Molar. 2. Buccal periodontal tissues and bone over these same teeth.	A. Pulps of the maxillary central incisor through the canine B. In about 72% of patients, pulps of maxillary premolars and mesiobuccal root of the first premolar C. Buccal periodontium D. Lower eyelid, lateral aspect of the nose, upper lip	(Soft tissue immediately adjacent to area of injection)
Indication	1- Pulpal anesthesia (1-2 teeth) 2- Soft tissue anesthesia	1- Two or more maxillary molars 2-Supraperiosteal injection is contraindicated (infection) 3- Supraperiosteal injection has proved ineffective	1- Procedures involving both maxillary premolars only 2- ASA nb fails to provide pulpal anesthesia distal to the maxillary canine	1- Two or more maxillary teeth 2- Supraperiosteal injection is contraindicated(infection) 3- Supraperiosteal injection has proved ineffective	1- Operative procedures on not more than two teeth 2- Palatogingival pain control of limited areas 3- Hemostasis during surgical procedures
Contraindication	-Infection or acute inflammation in the area of injection - Dense bone covering the apices of teeth	High risk of hemorrhage (as with a hemophiliac)	1- Infection or inflammation 2- If MSA nerve is absent, innervation is through ASA	1- Discrete treatment areas 2-Hemostasis of locaolized area is desirable	1- Infection or inflammation 2- Pain control in soft tissue areas involving more than two teeth (Large area)
Technique	Not mentioned	1) For a left PSA nerve block, a right-handed administrator should sit at the 10 o'clock position facing the patient. (2) For a right PSA block, a right-handed administrator should sit at the 8 o'clock position facing the patient.	For a right MSA nerve block, a right-handed administrator should face the patient from the 10 o'clock position. ii. For a left MSA nerve block, a right-handed admin- istrator should face the patient directly from the 8 or 9 o'clock position.	For a right or left infraorbital nerve block, a right-handed administra- tor should sit at the 10 o'clock position, directly facing the patient or facing in the same direction as the patient.	Position: A right-handed administrator should sit at the 10 o'clock position in front of patient)
Length of needle	Short needle (should be 2-4mm)	Short needle (long?)	Short needle	Long or (short ?)	Short needle
Area of insertion (landsmark)	Mucobuccal fold (+ crown & root)	Mucobuccal fold over 2nd molar, Maxillary tuberosity, Zygomatic process of maxilla	Mucobuccal fold above 2nd premolar	Mucobuccal fold over 1st premolar (central to 2nd premolar!) infraorbital notch and foramen	5-10 mm from free gingival margin Few millimeters
Orientation (syringe)	Parallel with long axis, toward bone	Direction: upward, inward, and backward at 45° angle	Not mentioned	Parallel with long axis	at 45 degree angle (to the alveolar bone
Depth of penetration	Few millimeters (4-5 mm)	16 mm – (10-14mm?)	Not mentioned	16 mm ?	Not mentioned
Target Area	Apical region	posterior, superior and medial to the maxillary tuberosity	Apex 2nd premolar	Infraorbital foramen	Not mentioned
Volume of LA solution	0.6 ml / 20 seconds	0.9-1.8 ml / 20-60 seconds	0.9-1.2 ml / 30-40 seconds	0.9-1.2 ml /30-40 seconds	0.2-0.3 ml
Sign and symptoms	Subjective : Numbness Objective : no pain, no response on electrical pulp test (EPT) or cold test	subjective: no sign Objective: no pain, no response (EPT)	Subjective: Numbness of upper lip Objective: no pain no response (EPT)	Subjective: 1- Numbness of upper lip, side of nose, lower eyelid 2- Numbness in the teeth and soft tissues along the distribution of the ASA and MSA nerves Objective: no pain no response (EPT)	Subjective: 1- numbness 2- Ischemia of palatal objective: No pain
Failures of Anesthesia	1- Technique: Needle tip below apex 2- Needle tip too far from bone 3- Amount: Not sufficient amount 4- Duration: take 2-3 minutes	1- Needle tip too lateral 2- Needle tip not high enough 3- Needle tip too far posterior	1- Needle tip below 2nd premolar apex 2- Needle tip too far from bone 3- Bone of the zygomatic arch at the site of injection	1- Needle tip contacting bone below the infraorbital foramen 2- Needle deviation medial or lateral to the infraorbital foramen	Inflamed tissue
Advantages	1- High success rate (> 95%) 2- Technically easy injection 3- Usually entirely a traumatic	1- High success rate (> 95%) 2- Atraumatic (Not painful) 3- Minimum number of necessary injections 4- Minimizes the total volume of local anesthetic	Minimizes the number of injections and the volume of solution.	1- Simple 2- Minimum number of necessary injections 3- Minimizes the total volume of local anesthetic	1-Acceptable hemostasis when a vasoconstrictor is used 2-Minimum area of numbness
Disadvantages	1- Not recommended for large areas 2- (multiple needle insertions 3- larger total volumes of local anesthetic)	1- Risk of hematoma "bleeding" 2-Need for second injection (1st molar) 3- Anesthesia of V3 (tongue-lower lip)	None	Psychological: fear for injury (dentist, patient) Anatomic: difficulty defining landmarks (rare)	Traumatic injection (Very painful)

	Greater palatine nb	Nasopalatine nb	Maxillary nb (2nd division nb)	Inferior alveolar nerve block (IANB)	The Gow-Gates technique
Other Names	Anterior palatine nerve block	Incisive nb, sphenopalatine nv	Second division block, V2 nerve block	Mandibular block	third division nerve block, V3 nb
Nerves Anesthetized	Greater palatine nerve	nasopalatine nerve bilaterally	Maxillary division of the trigeminal nerve.	1- Inferior alveolar 2- Incisive 3- Mental 4- Lingual	1- Inferior alveolar 2- Incisive 3- Menta 4- Lingual 5- Mylohyoid 6- Auriculotemporal 7- Buccal (in 75% of patients)
Area Anesthetized	((Palatial soft tissue and palatial bone but excluding teeth and pulp The posterior portion of the hard palate and its overlying soft tissues, anteriorly as far as the first premolar and From distal medially to the midline to the canine up to last molar))	anterior portion of the hard palate (soft and hard tissues) bilaterally from the mesial aspect of the right first premolar to the mesial aspect of the left second premolar	1.Pulpal anesthesia of the maxillary teeth on the side of the block 2- Buccal periodontium and bone overlying these teeth 3- Soft tissues and bone of the hard palate and part of the soft palate, medial to middle 4- Skin of the lower eyelid, side of the nose, cheek, and upper lip	1- Mandibular teeth to the midline 2- Body of the mandible, inferior portion of the ramus 3-Buccal mucoperiosteum, mucous membrane anterior to the mental foramen (mental nerve) 4- Anterior two-thirds of the tongue and loor of the oral cavity (lingual nerve) 5- Lingual soft tissues and periosteum (lingual nerve)	1.- Mandibular teeth to the midline 2- Buccal mucoperiosteum and mucous membranes on theside of injection 3- Anterior two-thirds of the tongue and loor of the oral cavity 4- Lingual soft tissues and periosteum 5- Body of the mandible, inferior portion of the ramus 6- Skin over the zygoma, posterior portion of the cheek,and temporal regions
Indication	1- Surgical and periodontal procedures involving palatal hard and soft tissue. 2- Necessity of palatal soft tissue anesthesia (>2 teeth) for restorative therapy (subgingival restoration)	1- Surgical and periodontal procedures involving palatal hard and soft tissue. 2- Necessity of palatal soft tissue anesthesia (>2 teeth) for restorative therapy (subgingival restoration)	- Extensive oral procedures - inflammation or infection - Diagnostic or therapeutic procedures for neuralgias	1- Procedures on multiple mandibular teeth in one quadrant 2- When buccal soft tissue anesthesia (anterior to the mental foramen) is necessary 3- When lingual soft tissue anesthesia is necessary	When a conventional inferior alveolar nerve block is unsuccessful
Contraindication	1- Infection or inflammation 2- Small area of therapy (1-2 teeth)	1- Infection or inflammation 2-Small area of therapy (1-2 teeth)	- Pediatric and uncooperativ patients - Inflammation or infection of tissues overlying the injection site - Risk of hemorrhage (hemophiliac) - Bony obstructions -Inexperienced administrator - In the greater palatine canal approach: inability to gain access to the canal	1- Infection or acute inlammation in the area of injection (rare) 2- Patients who are more likely to bite their lip or tongue	Patient who are unable to open their mouth wide
Technique	💡 For a right greater palatine nerve block, a right- handed administrator should sit facing the patient at the 7 or 8 o'clock position. ii. For a left greater palatine nerve block, a right-handed administrator should sit facing in the same direction as the patient at the 11 o'clock position.	Sit at the 9 or 10 o'clock position facing in the same direction as the patient	i For a right greater palatine canal V, Bloc sit facing toward the patient at the 7 or 8 o' clock position. A For a left greater palatine canal V, block, sit facing in the same direction as the patient at the 10 or 1 o'dock position.	For a right IANB, a right-handed administra- tor should sit at the 8 o'clock position facing the patient ii. For a left IANB, a right-handed administrator should sit at the 10 o'clock position facing in the same direction as the patient	For a right Gow-Gates mandibular nerve block, a right-handed administrator should sit at the 8 o'clock position facing the patient. ii. For a left Gow-Gates mandibular nerve block, a right- handed administrator should sit at the 10 o'clock posi-
Length of needle	Short needle	Short needle	Long needle	long	long
Area of insertion (landsmark)	greater palatine foramen and junction of the maxillary alveolar process and palatine bone	palatal mucosa just lateral to the incisive papilla	high-tuberosity approach A. Mucobuccal fold at the distal aspect of the maxillary second molar B. Maxillary tuberosity C. Zygomatic process of the maxilla * Greater palatine canal approach A. Greater palatine foramen, junction of the maxillary alveolar process and the palatine bobd	A. Cronoid notch (greatest concavity on the anterior border of the ramus) B. Pterygomandibular raphe (vertical portion) C. Occlusal plane of the mandibular posterior teeth	extraoral: A. The interragic notch (lower border of the tragus) B. Corner of the mouth on the contralateral side * intraoral A. Height of the injection established by placement of the needle tip just below the mesiolingual cusp of the maxillary second molar B. Penetration of the soft tissue just distal to the maxillary second molar
Orientation (syringe)	at a right angle, from opposite side of the mouth	at 45 -degree angle toward the insertion) incisive papilla	High-Tuberosity Approach: Direction: upward, inward and backward at 45° angle Greater Palatine Canal Approach : At a 45-degree angle Upward	corner of the mouth, corresponding to the premolars of opposite side	Not mentioned
Depth of penetration	5 mm	less than 5 mm	30 mm (aspiration is necessary)	20-25 mm	25 mm
Target Area	greater (anterior) palatine nerve	incisive foramen, beneath the incisive papilla	Pterygopalatine fossa	superior to the mandibular foramen within pterygomandibular space	Lateral side of the condylar neck, just below the insertion of the lateral pterygoid muscle
Volume of LA solution	0.45 to 0.6 mL	0.45 ml	1.8 ml / 60 seconds	1.5 ml /60 seconds + 0.2 ml	1.8-3ml /60-90 seconds (3ml) 5 minutes or longer (WHY?)
Sign and symptoms	Subjective: Numbness in posterior part of palate object: no pain	Subjective: Numbness in anterior part of palate object: no pain	Subjective: 1- Pressure behind the upper jaw 2- Numbness (lower eyelid, side of the nose, upper lip, buccal and palatal soft tissues) Object: 1- no pain 2- no response EPT	Subjective: 1- numbness of the lower lip 2- numbness of the tongue Objective: 1- No pain	Subjective: 1- numbness of the lower lip 2- numbness of the tongue Objective: 1- No pain
Failures of Anesthesia	- Needle tip too far anterior to forame - Overlapping fiber from nasopalatine nerve (fist premolar area)	- solution is deposited to one side of the incisive canal (unilateral anesthesia) - Overlapping fiber from greaterpalatine nerve (canine area)(inadequate anesthesia)	- Inability to negotiate the greater palatine canal - Underpenetration by needle	1- Incorrect technique 2- Inflammation 3- Apprehensive patient 4- Intravascular injection 5- Anatomical variability (high foramen, flare of rams) 6- Overlapping fiber of contralateral IAN 7- Accessory innervation or bifid IAN	1- Too little volume 2- Anatomic difficulties
Advantages	- Minimizes needle penetrations and volume of solution - Minimizes patient discomfort - single injection		1- Minimizes needle penetrations and volume of solution 2- Minimizes number of needle penetration 3- High success rate	One injection provides a wide area of anesthesia	1- Requires only one injection 2- High success rate (>95%), with experienc 3- Few postinjection complications (e.g., trismus) 4- Minimum aspiration rate (2%) 5- Provides successful anesthesia where a bifid inferior alveolar nerve and bifid mandibular canals are present.
Disadvantages	- No hemostasis except in the immediate area of injection -pain	Same it	1- Penetration of the orbit and the nasal cavity 2- Risk of Hematoma 3- Lack of hemostasis	1- Wide area of anesthesia 2- Lingual and lower lip anesthesia 3- Intraoral landmarks not consistently reliable 4- Positive aspiration (10-15%, highest of all intraoral injection techniques) 5- Rate of inadequate anesthesia (31% to 81%) 6- Partial anesthesia possible	1- Lingual and lower lip anaesthesia 2- The time to onset of anaesthesia is somewhat longer

	Vazirani-Akinosi Closed-Mouth nb	Incisive nerve block	Buccal nerve block	🙌🙌🙌
Other Names	1- closed-mouth mandibular nb 2- tuberosity technique	Mental nerve block (inappropriate)	1- Long buccal nerve block 2- buccinator nerve blocks	Other Names
Nerves Anesthetized	1- Inferior alveolar 2- Incisive 3- Mental 4- Lingual 5- Mylohyoid	1- incisive 2-Mental	Buccal	Nerves Anesthetized
Area Anesthetized	1- Mandibular teeth to the midline 2- Body of the mandible and inferior portion of the ramus 3- Buccal mucoperiosteum and mucous membrane anterior to the mental foramen 4- Anterior two-thirds of the tongue and loor of the oral cavity (lingual nerve) 5- Lingual soft tissues and periosteum (lingual nerve)	1. Buccal mucous membrane anterior to the mental fora-men, usually from the second premolar to the midline 2. Lower lip and skin of the chin 3. Pulpal nerve ibers to the premolars, canine, and incisors	Soft tissues and periosteum buccal to the mandibular molar teeth	Area Anesthetized
Indication	1- Limited mandibular opening 2- large tongue	1- Dental procedures requiring pulpal anesthesia of mandibular teeth anterior to the mental foramen 2- When IANB is not indicated: 3- When 6, 8, or 10 anterior teeth (e.g., canine to canine or premolar to premolar) are treated, the incisive nerve block is recommended in place of bilateral IANBs.	When buccal soft tissue anesthesia is necessary for dental procedures in the mandibular molar region.	Indication
Contraindication	Inability to visualize or gain access to the lingual aspect of the ramus	Infection or acute inlammation in the area of injection.	Infection or acute inlammation in the area of injection.	Contraindication
Technique	Assume the correct position. For a right or a left Vazi-rani-Akinosi closed-mouth mandibular nerve block, a right-handed administrator should sit at the 8 o'clock position facing the patient.	for a right or left incisive nerve block and a right-handed administrator, sit comfortably in front of the patient so that the syringe may be placed into the mouth below the patient's line of sight	For a right buccal nerve block, a right-handed administrator should sit at the 8 o'clock positiondirectly facing the patient ii. For a left buccal nerve block, a right-handed administrator should sit at 10 o'clock facing in thesame direction as the patient	Technique
Length of needle	long	short	long	Length of needle
Area of insertion (landsmark)	A. Mucogingival junction of the maxillary third or second molar B. Maxillary tuberosity C. Coronoid notch on the mandibular ramus	Mucobuccal fold at or just anterior to the mental foramen	Mucous membrane distal and buccal to the most distal molar tooth in the arch	Area of insertion (landsmark)
Orientation (syringe)	Not mentioned	toward bone	toward bone	Orientation (syringe)
Depth of penetration	25 mm ?	5-6 mm, no need to enter the mental foramen or to contact bone.	1-4 mm	Depth of penetration
Target Area	mid-portion of the pterygomandibular space	Mental foramen	Buccal nerve as it passes over the anterior border of the ramus	Target Area
Volume of LA solution	1.5-1.8 ml /60 seconds	0.6-0.9 ml /20 seconds	0.3ml /10 seconds	Volume of LA solution
Sign and symptoms	Subjective: 1- numbness of the lower lip 2- numbness of the tongue Objective: 1- No pain	Subjective: 1- numbness of the lower lip Objective: 1- No pain	A. Subjective: none B. Objective: no pain	Sign and symptoms
Failures of Anesthesia	1- flaring nature of the ramus 2- needle insertion point too low 3- under insertion or over insertion of the needle (no bone contact)	1- Inadequate volume of anesthetic solution 2- Inadequate duration	inadequate volume of anesthetic retained in the tissue	Failures of Anesthesia
Advantages	1- Relatively atraumatic 2- Closed mouth 3- Fewer postoperative complications (e.g., trismus) 4- Lower aspiration rate (<10%) 5- Provides successful anesthesia where a bifid inferior alveolar nerve and bifid mandibular	A. Provide pulpal and osseous anesthesia without lingual anesthesia (lingual anesthesia is uncomfortable and unnecessary for many patients); useful in place of bilateral IANBs B. High success rate	A. High success rate B. Technically easy	Advantages
Disadvantages	1- Difficult to visualize the path and depth of insertion 2- No bony contact	A. Doesn't provide lingual anesthesia B. Partial anesthesia may develop at the midline because of nerve fiber overlap with the opposite side	A. Potential for the pain if the needle contacts the periosteum during injection	Disadvantages